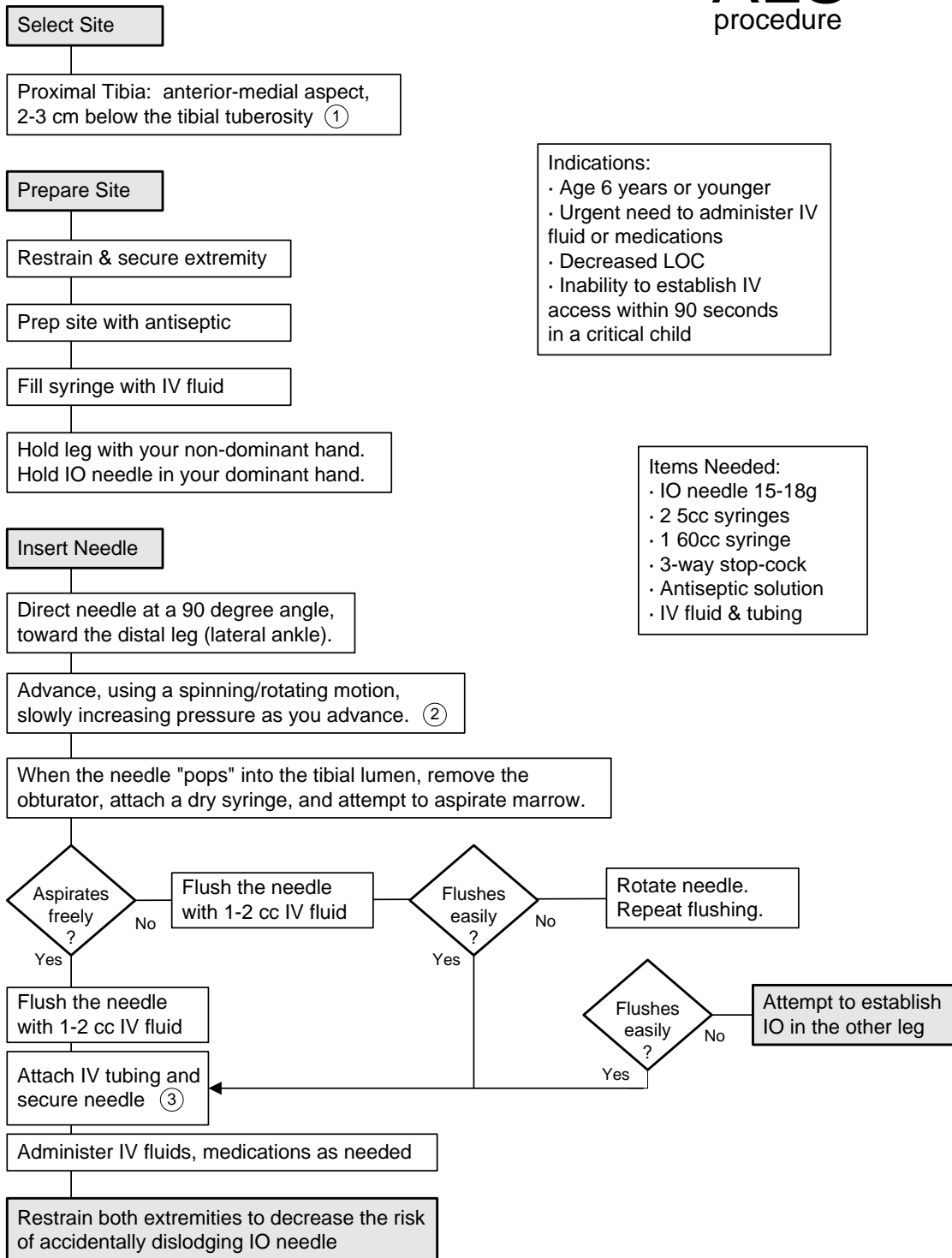


Intraosseous Infusion: Pediatric

ALS procedure



1 Alternate site: distal tibia; anterior-medial aspect, 2-3 cm proximal to the medial malleolus.

2 Avoid a rocking motion!

3 Use a 3-way stop-cock and a 60 cc syringe to administer IV fluid via boluses.